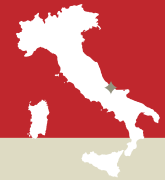

# Eucharistic Miracle of LANCIANO

ITALY, 750 A.D.




An inscription in marble from the 17th century describes this Eucharistic miracle which occurred at Lanciano in 750 at the Church of St. Francis. “A monastic priest doubted whether the Body of Our Lord was truly present in the consecrated Host. He celebrated Mass and when he said the words of consecration, he saw the Host turn into Flesh and the Wine turn into Blood. Everything was visible to those in attendance. The Flesh is still intact and the Blood is divided into five unequal parts which together have the exact same weight as each one does separately.



Monstrance containing the Holy Relics



Relic of the wine which was transformed into Blood



Painting located in the Valsecca chapel which depicts the miracle



Stone tablet from 1631 which describes the miracle



In 1970, the Archbishop of Lanciano and the Provincial Superior of the Conventual Franciscans at Abruzzo, with Rome's approval, requested Dr. Edward Linoli, director of the hospital in Arezzo and professor of anatomy, histology, chemistry, and clinical microscopy, to perform a thorough scientific examination on the relics of the miracle which had occurred twelve centuries earlier. On March 4, 1971, the professor presented a detailed report of the various studies carried out. Here are the basic results:

1. The “miraculous flesh” is authentic flesh consisting of muscular striated tissue of the myocardium.
2. The “miraculous Blood” is truly blood. The chromatographic analysis indicated this with absolute and indisputable certainty.
3. The immunological study shows with certi-

tude that the flesh and the blood are human, and the immuno – hematological test allows us to affirm with complete objectivity and certitude that both belong to the same blood type AB, the same blood type as that of the man of the Shroud and the type most characteristic of Middle Eastern populations.

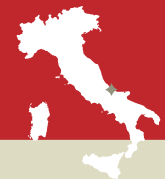4. The proteins contained in the Blood have the normal distribution, in the identical percentage as that of the serous-proteic chart for normal fresh blood.

5. No histological dissection has revealed any trace of salt infiltrations or preservative substances used in antiquity for the purpose of embalming. Professor Linoli also discarded the hypothesis of a hoax carried out in past centuries. This report was published in *The Sclavo Notebooks in Diagnostics* (Collection #3, 1971) and aroused

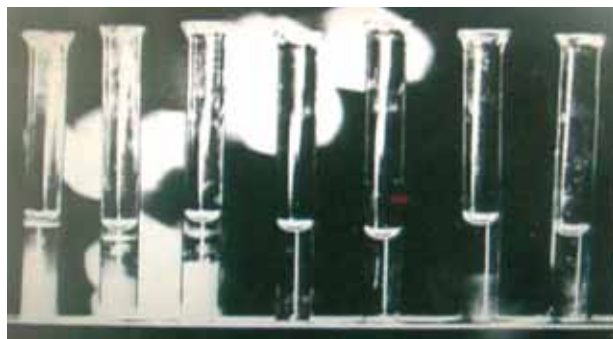great interest in the scientific world. Also, in 1973, the chief Advisory Board of the World Health Organization appointed a scientific commission to corroborate Linoli's findings. Their work lasted 15 months and included 500 tests. It was verified that the fragments taken from Lanciano could in no way be likened to embalmed tissue. As to the nature of the fragment of Flesh, the commission declared it to be living tissue because it responded rapidly to all the clinical reactions distinctive of living beings. Their reply fully corroborated Professor Linoli's conclusions. In the extract summarizing the scientific work of the Medical Commission of the WHO and the UN, published in Dec. 1996 in New York and Geneva, declared that science, aware of its limits, has come to a halt, face to face with the impossibility of giving an explanation.

# Eucharistic Miracle of LANCIANO

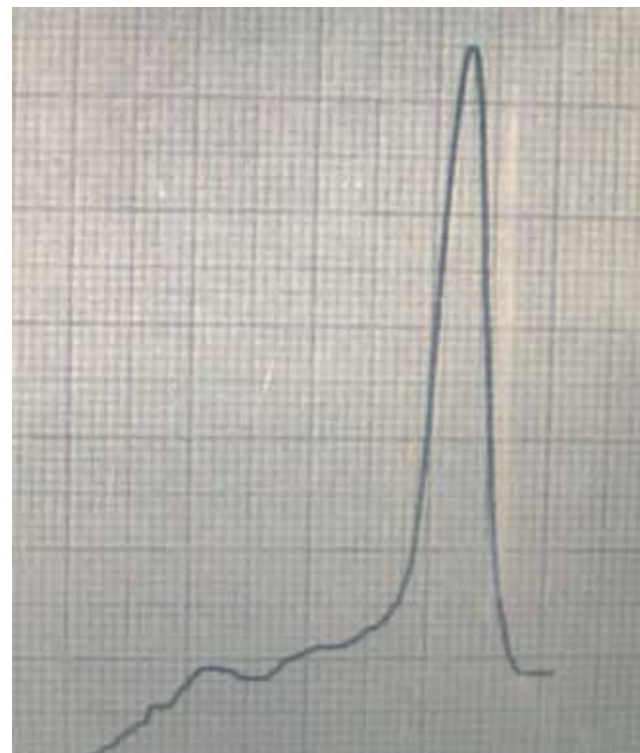
ITALY, 750 A.D.



*The Flesh and the Blood of Lanciano therefore are just the same as they would be if they had been drawn that very day from a living being.*



The reliquary from the 18th century containing the Host and the coagulated Blood, gift of the generous citizen Domenico Coli



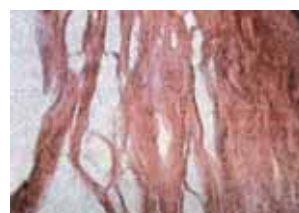Graph of the electrophoresis of the proteins of the Blood of the Miracle. The profile of the protein fractions from the serum could be superimposed on a standard specimen of fresh blood



The 5 clots of Blood as seen with a magnifying glass. In the blood of the Miracle can be recognized all the components present in fresh blood, and the miracle within the miracle, each of the 5 clots of Blood weighs 15.85 grams, which is the identical weight of the 5 clots weighed together!



The muscular fiber cells



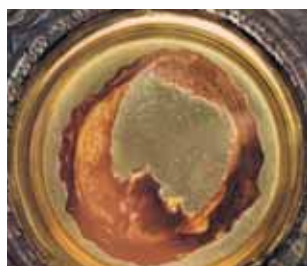Histological view of the Flesh



The Church of St. Francis was constructed almost 500 years later, in 1258, above the chapel where the miracle took place



The flesh consists of part of the myocardium, more precisely of the left ventricle. The arteries and veins can be easily identified, as well as a double, slender branch of the vagus nerve. At the time of the miracle, the flesh was living and then submitted to the law of rigor mortis.



The miracle was the object of several official acknowledgements on the part of the ecclesiastical authorities between 1574 and 1886, not to mention most recently, in 1970, when it was subjected to a scientific examination carried out by professors from the University of Siena, which concluded: "The flesh is true human flesh (formed by muscular tissue from the heart); that the blood is true blood (belonging to the same blood type AB as the flesh); that the component substances are those of human tissues, normal and fresh; that the conservation of the flesh and the blood, left in their natural state for twelve centuries and exposed to the influence of atmospheric and biological elements, remains an extraordinary phenomenon" (The Linoli Report 4131971).



A vagus nerve



Analysis of the Host. Endocardiac structures



A small lobe of adipose tissue



Il Reverendo Pontefice Giovanni Paolo II allora Cardinale di Cracovia davanti alla Ss. Reliquia, con esposizione in sua invocazione: 3.21.1979



Cubical lattice in gold-plated cast iron in which the relics were preserved for almost 266 years, today returned to the Valsecca family chapel



An antique painting depicting the Miracle